

Reversal of Residual Stroke Symptoms Using Hyperbaric Oxygen Therapy

Morton Walker, D.P.M.

Homemaker Maureen Phosfeld of Montgomery, Alabama, has been married to Sandford (Sandy) Phosfeld for 34 years. Her husband remained a robust and vigorous railroad dispatcher until he was 58 years old. Then, on February 19, 1986, he experienced a severe cerebral vascular insult (CVI) to the right side of his brain. The stroke caused him hemiplegia along the entire left half of his body and disabled his right arm. Diagnosed by the City of Montgomery's hospital neurologist as having a progressive form of stroke, which is the most deadly type of stroke, Mr. Phosfeld was not expected to live. As described by Mrs. Phosfeld, her husband's condition seemed to be hopeless:

My husband lay in that hospital bed for over a month and slept the entire time. He hardly ever opened his eyes and spoke not at all. He was speechless and without expression. His attending physicians told me that it was as far as Sandy would ever come in returning to the real world. They advised me to institutionalize him because he required 24-hour nursing care, something I thought I couldn't manage at home.

Editor's note: Parts of this article are excerpted from a manuscript by the author in consultation with Richard E. Neubauer, M.D., as contracted with the Avery Publishing Group, Inc., of Garden City Park, NY. Their book will be published in May 1996 under the title *HBO: The Benefits of Hyperbaric Oxygen Therapy*.

So, I did place my husband with a rehabilitation center as a full-time resident. While there, however, he fell out of his wheelchair three times because of insufficient supervision by the nursing staff. He had no movement ability or coordination and couldn't resist the force of gravity. So I took him out of the institution I was nursing him myself, feeding through a nasogastric tube, washing his body, and doing all the other jobs one must perform for a helpless individual. A physical therapist came in regularly for a time, but nothing seemed to help Sandy come back to himself.... He was officially classified by a representative of the Veterans Administration as totally bedridden, beyond rehabilitation; [he was, in essence,] "a vegetable" with the poorest prognosis.

Then Mrs. Phosfeld read about a new kind of stroke therapy:

But then, in February 1992, I read in my city newspaper about hyperbaric oxygen as a viable treatment for stroke, so I telephoned for an appointment and traveled with Sandy to the pressurized oxygen facility described. It operated six single-person hyperbaric chambers in a clinic located at Lauderdale-by-the-Sea, Florida, under the direction of hyperbaricist Richard E. Neubauer, M.D. Naturally I didn't expect miracles, only I was hoping that my husband would learn to speak my name or swallow a sip of water or turn in the bed by himself. I just wanted to see him acting like a human being again. I prayed that hyperbaric oxygen therapy-HBOT, as it's labeled in medical shorthand-might do that.

By the end of 13 hyperbaric oxygen treatments, nothing much had happened ex-

cept that Sandy showed a growing agitation. He had awakened out of his lethargy and wanted something from me but made nothing known. Then, suddenly, after his fourteenth HBOT, he amazed the clinic staff, Dr. Neubauer, and me. Sandy spoke words to us. That evening he turned himself over in bed, became progressively active during each day, and actually participated in his physical therapy sessions. He cooperated with the therapists and moved parts of his body that had been immovable before. In another week, he used his legs to push himself in the wheelchair around Dr. Neubauer's Ocean Hyperbaric Center. He spoke whole sentences, moved his left arm, and squeezed a rubber ball. His right arm, which had been drawn up in a hooklike position, relaxed, and the fingers loosened their contraction....

We returned to Montgomery after he had undergone 20 hyperbaric oxygen treatments through March 1992. His improvement was dramatic. He spoke without slurring words, ate full meals, remained awake during most of the daylight hours, and once more became my companion.

Acting on Dr. Neubauer's referral, Mrs. Phosfeld found another hyperbaric chamber facility not too far from their home, and Mr. Phosfeld continued his treatments. Although he has not returned to work, he has been rehabilitated at least 90 percent. HBOT was the main instrument of his recovery. It returned Sandford Phosfeld to a stable condition so that now he gets around on his own, tends his garden, plays golf, visits with his grandchildren, and fulfills his personal needs like any retired person.

Usual Stroke Prognosis and Why This Patient Bested It

Stroke outranks head injury today as the leading cause of neurologic disability among those living in industrialized Western countries. For the past 30 years it has been the third most frequent cause of death in the United States and the single most expensive disease.¹ Figuring in the costs of physicians' services, nursing homes, and other nonhospital care, stroke costs about \$33 billion a year. According to the American Heart Association, the condition strikes more than 500,000 Americans annually, causing death in 150,000. More than 3 million Americans are living with varying degrees of disability caused by stroke.²

From 15 percent to 58 percent of stroke victims die within 30 days of being struck by a cerebrovascular accident (CVA). Of stroke survivors, only 10 percent manage to return to work without some disability, 40 percent experience mild disability, 40 percent are severely disabled, and 10 percent require either temporary or permanent institutionalization. At this time, in medical practice, none of the stroke management methods or the various sequelae treatment techniques can be considered satisfactory.³ The result is that a certain pessimistic attitude toward stroke pervades the medical profession overall.

"Treatment of stroke is nearly a decade behind the treatment of heart attacks," says Michael D. Walker, M.D., director of the Division of Stroke and Trauma of the National Institute of Neurological Disorders and Stroke, Bethesda Maryland. "The vast majority of physicians have been taught that brain damage caused by stroke is irreversible. As a result, little effort was expended on figuring out what was going on.

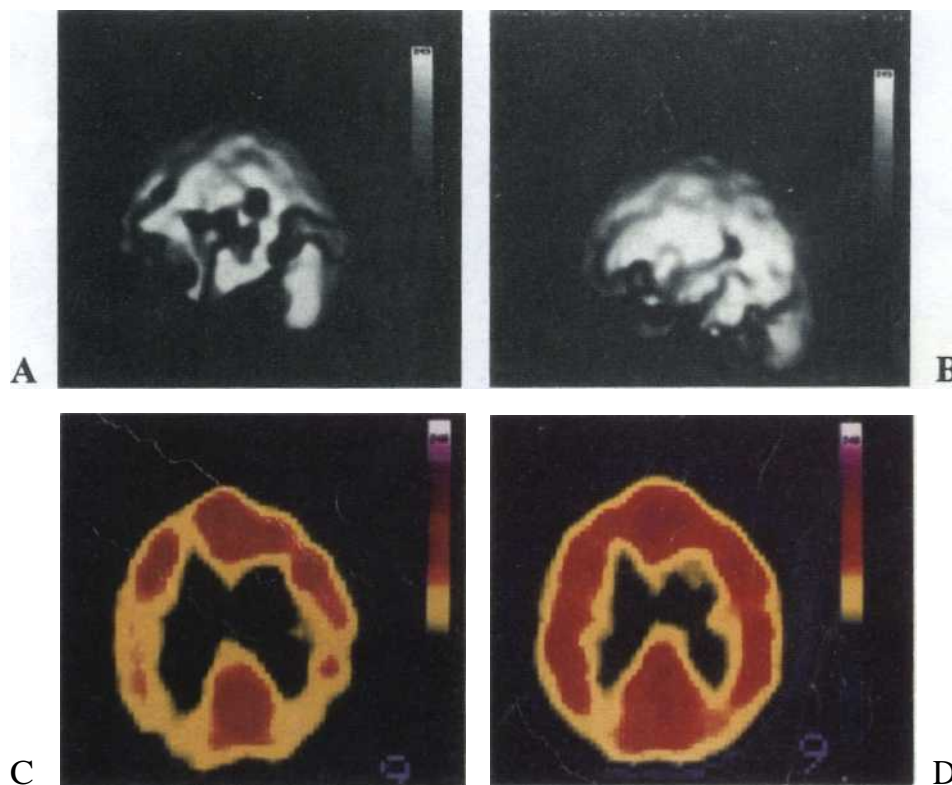


Figure 1. Shown are four SPECT scans of Mr. L.A.F., a 78-year-old retired school teacher from Ft. Lauderdale, Florida, who experienced the acute onset of left-sided weakness, dizziness, inability to stand, and mental confusion.

- The initial computer-generated, three-dimensional, pre-HBOT SPECT scan of the brain, which reveals diffuse diminished activity throughout the lower gyre of the frontal lobes, worse on the left and throughout the temporal lobes, left basal ganglion, and posterior occipital poles. Notice the large holes, which indicate that an acute ischemic stroke has taken place in the middle of an ischemic cascade. The holes occurred in the brain because there was a lack of blood and oxygen perfusing those damaged areas. This is the exact location of the patient's deficit.
- Three-dimensional post-HBO SPECT scan of the same patient 1 hour later, following his treatment with hyperbaric oxygen therapy (HBOT). The holes are gone because they are filled with blood and oxygen. The ischemic thrombotic portion has completely cleared.
- The brain's axial view before Mr. L.A.F. received HBOT. Notice the brain's yellow and red areas. Yellow areas indicate greatly reduced blood and oxygen. The patient has experienced a major stroke.
- Axial view of the same brain after Mr. L.A.F. underwent just one HBO treatment for 1 hour at 1.5 ATA.

"Only recently have we begun to understand some basic facts about strokes. We know that the area in the middle [of the brain area affected by] the stroke is often fully infarcted, and it will die, but the area at the periphery may be salvaged if we move quickly," said Dr. Walker. This area of viable neurons is known as the ischemic penumbra. "We're quite sure now," he added, "that although the

specifics vary from patient to patient, there are areas of the brain that aren't dead but instead are in an idling condition. The area is not electrically active, but it has the potential, like an idling car, to be brought back up to speed. But you can't wait very long."

The immediate goal of emergency brain resuscitation is to limit damage and restore the neurons in the ischemic penum-

Length of Hospital Stays for 18 Patients Treated Within 4 Hours of Ictus

| Standard Treatment | | HBO Treatment | |
|--------------------|-------------|-----------------|-------------|
| No. of patients | No. of days | No. of patients | No. of days |
| 1 | 5 | 4 | 0 |
| 1 | 8 | 1 | 5 |
| 2 | 10 each | 1 | 9 |
| 2 | 11 each | 1 | 10 |
| 2 | 14 each | 2 | 12 each |
| 1 | 17 | 2 | 15 each |
| 2 | 19 each | 2 | 20 each |
| 1 | 24 | 1 | 16 |
| 2 | 40 each | 1 | 26 |
| 1 | 44 | 1 | 34 |
| 1 | 47 | 1 | 30 |
| 1 | 48 | | |

Total number of days=381 Total number of days=224

Treatment Outcomes for Acute Stroke in 16 Patients

| | Standard Treatment | Standard Treatment + HBO Treatment |
|--------------|--------------------|------------------------------------|
| Expired | 2 | 1 |
| Nursing home | 8 | 0 |
| Home | 6 | 15 |

Current Methods of Spasticity Management

Physical medicine

- Physical modalities: heat, cold, vibration, electrical stimulation
- Physical therapy: use of proper splints, positioning of patient, spasm-inhibiting exercises, slow and prolonged stretch

Drugs

Dantrolen, baclofen, diazepam, warfarin, heparin, phenytoin plus chlorpromazine

Surgery

- Orthopedics: lengthening, sectioning, tendon release, transposition of tendons
- Neurosurgical: intramuscular neurolysis and rhizotomy, spinal cord stimulation

Three Principal Reasons for Stroke to Strike

The three main reasons for stroke to occur are vascular in origin-ischemia, hemorrhage, and emboli.

Ischemia is a lack of oxygen and glucose carried through the circulating blood to the brain, which may result from arterial stenosis or thrombosis. Ischemic or thrombotic strokes injure only a certain area of the brain supplied by the affected blood vessel and, in so doing, cause a specific functional impairment.

Hemorrhage is brain bleeding from burst blood vessels, which impairs the circulation of blood oxygen and glucose to a single area of the brain's hemispheres. Massive hemorrhage may destroy large areas, causing rapid loss of consciousness and death. Hypertension or blood vessel abnormalities can bring on a cerebral hemorrhage.

Emboli are blood clots that may form in the heart valve, in the carotid arteries, or on the inner heart surface and travel to the brain. Such clots sometimes develop from a heart attack, a heart valve infection, or rheumatic heart disease.

bra. How much time is available to complete the salvage operation? "That depends on how low the supplies of oxygen and glucose get and how long the condition is maintained," Dr. Walker says. "It's no different from what occurs in the myocardium during a [myocardial infarction]."⁴

Visualizing the Ischemic Penumbra with SPECT Scanning

Six years after his stroke occurred, Mr. Phosfeld was given access to two major medical advances, one diagnostic advance that determined the viability of his ischemic penumbra and the other a therapeutic advance that nourished that penumbra with oxygenation. These procedures allowed him to overcome his residual stroke symptoms (sequelae).

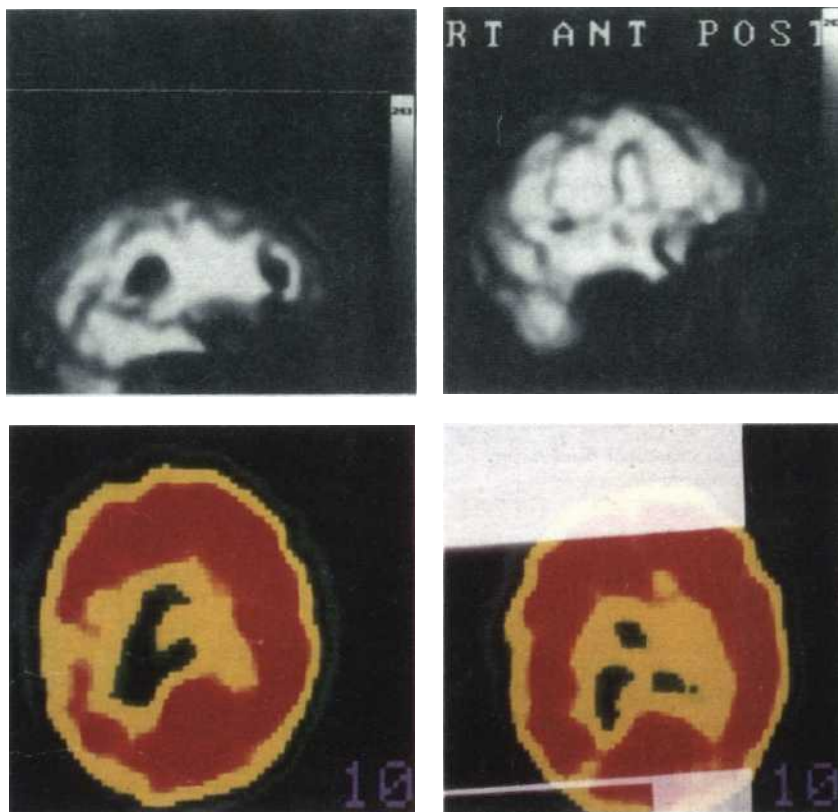
More effective for visualizing the internal functional structures of the brain than either computed tomography (CT) or magnetic resonance imaging (MRI) is single photon emission computed tomography (SPECT), with the addition of a special radiotracer element, technetium-^{99m}HMPAO [Tc-^{99m}, dl-hexamethylpropyleneamine oxime], commercially known as Ceretec® (Amersham Co., Arlington Heights, Illinois). Together, SPECT and the tracer allow for observing both local and global evolutionary changes in the brain following stroke most accurately.

Recovery from the global phenomena of stroke and the ability to predict its outcome are directly related not only to tissue damage, but also to the ischemic penumbra. Such changes may be recognized with SPECT 3 months following the stroke. Furthermore, newer tracers that measure the metabolic activity of the

brain's gray matter have demonstrated spontaneous or natural changing tracer activity for up to 6 months.'

Within an assaulted brain, the injured area is surrounded by a margin of tissue that fans out and looks like an atomic bomb blast. A center core may be lost, but the marginal tissue often retains various degrees of viability or function. The outlook and overall prognosis of stroke depend largely on the remaining viable areas in this ischemic penumbra. Perfusion with tissue oxygen reactivates idling neurons. These damaged and dormant nerve cells are metabolically lethargic and electrically nonfunctional but remain viable in the ischemic penumbra. They have been subjected to critical low tissue oxygen availability. By correction of oxygen deficiencies, idling neurons become metabolically stimulated to regain electrical function.⁶

Improved metabolism has been seen in stroke patients with midbrain infarction using SPECT scanning. Dr. Neubauer is the originator of the technique for color coding, digitalizing, identifying, and observing the ischemic penumbra. The existence of an ischemic penumbra had been mere conjecture until Dr. Neubauer demonstrated its presence with SPECT. He has become an advocate of the use of hyperbaric oxygen (HBO) as the therapeutic means of awakening idling neurons in stroke. For example, in a patient who experienced a stroke 13 years previously who showed hemiplegia, mental confusion, drooling, and speech impairment, there was improvement in metabolism and better function in the ischemic brain area following a single exposure of HBO at 1.5 atmospheres absolute (ATA) administered for 60 minutes.⁷



C

Figure 2. Four SPECT scans are shown of Mrs. C.G., an 84-year-old retired physical therapist from Delray Beach, Florida, who sustained a stroke 3 months earlier on the right side of her brain. Her left side was paralyzed. She was having great difficulty with her memory, but she was not institutionalized after the initial hospitalization.

- Mrs. C.G.'s computer-generated, three-dimensional, pre-HBOT SPECT scan, showing two large holes in her brain caused by the absence of blood and oxygen as the result of the cerebral vascular accident that happened 3 months previously.
- The same 3-D view of the patient's brain following three treatments with HBO for 1 hour each at 1.5 ATA. Notice that Mrs. C.G.'s brain damage has largely disappeared, with the brain's recovery improved by approximately 98 percent.
- Axial view of Mrs. C.G.'s brain 3 months after she sustained left side hemiplegia from deficit in the area of the right midcerebral flow. The pretreatment midcerebral slice of film taken by the SPECT scan indicates that her deficit is not as great as that of L. A. F., although Mrs. C.G.'s brain damage had been present much longer.
- Axial SPECT scan of the same woman taken posttreatment with HBO. Note how the vacant yellow areas have been filled in and turned red, indicating increased perfusion and metabolism. Three treatments with HBO at 1.5 ATA were given to Mrs. C.G., each lasting 1 hour. With an additional 20 HBO treatments, her situation became vastly improved, as did the clinical parallel that she followed.

Pathophysiologic Considerations

Stroke treatment must take into account that outcome depends on the site and extent of ischemic penumbral zones. The outcome may be predicted to some extent by the amount of damage to brain cells and how many are affected. Comparative

functional volume obtained by SPECT before and after 1 hour of 1.5 ATA HBOT often indicates a larger region of potentially recoverable edematous and hypoxic brain tissue.⁸ Pathophysiologic considerations dictate the use of HBO or, at least, unpressurized (isobaric) oxygen. Chronic neurologic deficits may benefit from

More than 1000 patients who sustained cerebrovascular disease have been treated with HBOT and have shown improvement that ranges from 40 percent to 100 percent.

Current Methods of Managing Stroke

Improvement of cerebral perfusion

Rheology for better blood flow
Antiplatelet aggregants
Anticoagulants, such as heparin
Thrombolytic therapy, such as tissue plasminogen activator (TPA)
Vasodilators

Cellular protection against hypoxia/ischemia

Calcium channel blockers
Barbiturate coma
Free radical scavengers
Lazeroid compound

Drugs to treat risk factors for stroke, such as antihypertensives

Drugs against cerebral edema

Cerebral stimulants to increase motor power in hemiplegia
Amphetamine

Drugs to improve cerebral metabolism

Neurotropics

Conventional Surgical Interventions for Stroke

Relief of intracranial pressure
Evacuation of intracerebral hematomas
Decompressive craniotomy

Removal of causative lesions
Carotid endarterectomy
Embolectomy

Surgical revascularization

Extracranial/intracranial bypass

Rehabilitation

Physical therapy
Occupational therapy
Speech therapy

TIA: The Primary Warning of an Impending Stroke

The main warning signal of an impending stroke is multiple transient ischemic attacks (TIAs). The most important factor in the stroke-prone profile of a potential victim. An educated estimate among medical experts is that approximately 35 of every 100 persons who experience TIA will suffer from a lethal or incapacitating stroke within 5 years. This number was confirmed from a statistical analysis of stroke patients who visited the Mayo Clinic in Rochester, Minnesota.

TIA, a miniature or temporary stroke in a localized brain area, may last 2-15 minutes, although it could be prolonged for 24 hours. The individual with TIA usually is normal following an attack and does not feel any persistent aftereffects. The TIA is dangerous, however, since it is produced by a blocked blood vessel, a blood clot vascular spasm, or the buildup of blood fats.

Symptoms of TIA to watch for

- Disturbed vision in one or both eyes
- Dizziness
- Unconsciousness
- Physical weakening
- Difficulty in swallowing
- Numbness and spontaneous tingling (paresthesia)

HBOV The treatment should be directed at potentially reversible brain tissue damage.

Because most patients with stroke possess idling neurons that are long lasting, there is no time limit for which therapeutic

intervention might be tried, especially if the comparative pre-HBOT and post-HBOT SPECT images suggest the presence of potentially recoverable brain tissue.⁹ Idling damaged neurons are found in all types of head injury and show reversal of periinfarctional/periinjury zones even after 15 years.⁷ Reported in the literature is a case of restoration of vision, years after its loss, by extracranial-intracranial anastomosis⁸ and another case of spontaneous arousal from long-term coma by reactivation of idling neurons, rather than by brain regeneration. HBOT can bring about such seemingly spontaneous corrections.

Treatment with HBO also has numerous other attributes for the stroke-impaired individual that cannot be duplicated by any other known drug. For brain pathophysiologies, oxygen under pressure:

Overcomes ischemia/hypoxia and breaks the ischemic cascade
Reduces cerebral edema, thereby enhancing local blood flow with its improved nutrient delivery and removal of metabolic waste products

Restores the integrity of the blood-brain barrier and cell membranes

Stimulates cell transport mechanisms and cell metabolism, thereby ameliorating local acidosis while improving neuronal function and aiding neuronal plasticity

Scavenges free radicals

Neutralizes toxic amines

Promotes phagocytosis, fibroblast proliferation, and collagen production

- Stimulates angiogenesis 11

As an international lecturer on hyperbaric oxygenation and the primary exponent of HBOT for stroke management in the United States, Dr. Neubauer affirms that stroke and other brain injuries share a common pathophysiology. Therefore, successful stroke management should include evaluation by initial and delayed SPECT imaging. Identification of potentially recoverable brain tissue warrants every effort at restoring a stroke patient to good health.

HBOT for Successful Management of Stroke

The deficiency of necessary brain oxygen in stroke causes neuronal malnourishment and subsequent dysfunction, and administration of oxygen under pressure reverses hypoxia for the brain tissues of stroke patients. The functions of HBOT that ensure the successful recovery of stroke patients include:

Relief of hypoxia-The damage to neurons that accompanies ischemia is repairable if associated hypoxia is corrected within a reasonable period of time. Because blood flow to the ischemic area cannot be restored immediately, the only way to get oxygen into the ischemic tissues is by increasing the rate and distance of oxygen diffusion through the marginal trickle of blood flow. HBO provides the means for increasing the amount of oxygen carried by the trickling capillaries. Oxygen delivered under pressure from a hyperbaric chamber nourishes the

Professional Organizations and Information Resources

Ocean Hyperbaric Center

Richard A. Neubauer, M.D., Medical Director
4001 Ocean Drive
Lauderdale-by-the-Sea, FL 33308
(305) 776-5800, (800) 552-0255
Fax: (305) 776-0670

Dr. Neubauer uses six monoplace hyperbaric chambers at his Clinical Baromedical Center, Inc. He is past president of the American College of Hyperbaric Medicine, past president of the Gulf Coast Chapter of the Undersea and Hyperbaric Medical Society, and previous board chairman of the International Society of Hyperbaric Medicine.

Undersea and Hyperbaric Medical Society (OHMS)

Leon Greenbaum, Ph.D., Executive Director
10531 Metropolitan Avenue
Kensington, MD 20895
(301) 942-2980
Fax: (301) 942-7804

The UHMS makes available a directory of hyperbaric treatment chambers from around the world. There are approximately 200 chamber facilities administering HBOT in the United States and perhaps 2000 worldwide.

American College of Hyperbaric Medicine

Virginia Neubauer, Executive Director
4001 Ocean Drive
Lauderdale-by-the-Sea, FL 33308
(305) 771-4000, (800) 552-0255
Fax: (305) 776-4682

ACHM members encourage the use of bodies of information on HBOT based on longitudinal data as well as case histories, patient studies, individual patient stories, and other aspects of the human condition. Double-blind, placebo-controlled studies are not considered mandatory but are acceptable.

The Agency for Health Care Policy and Research (AHCPR) United States Public Health Service

Dr. Clifton R. Gaus, Administrator
P.O. Box 8547
Silver Spring, MD 20907
(800) 358-9295

AHCPR offers guidelines, such as reference books for health professionals and consumers, written in English or Spanish, which describe poststroke rehabilitation. Request copies from AHCPR Publications Clearinghouse at the above address or telephone number.

National Institute of Neurological Diseases and Stroke

9000 Rockville Pike
Building 31, Room BA 16
Bethesda, MD
(800) 352-9424

As a predictive test, response to HBO is a positive sign of reversibility of the brain lesion and an indicator of continuing improvement after cerebral revascularization.

tissues even when there is an absence of red blood cells.¹²

Improvement of microcirculation-Following a stroke, the patient's microcirculation is disturbed, particularly in the infarcted area. The treatment rationale requires improving the microcirculation, and HBOT manages this correction by reducing blood viscosity, decreasing platelet aggregability, increasing red blood cell deformability, and speeding along blood flow in the tiniest of capillaries.¹³

Extravascular diffusion of oxygen-Under hyperbaric conditions, oxygen can diffuse extravascularly. Though the distance of diffusion is small, the extent can be considerable in an organ, such as the brain, which has a rich capillary network. It relieves hypoxia after occlusion of the major blood vessels of the brain.¹⁴

Relief of cerebral edema-HBOT reduces cerebral edema, is nontoxic, and causes vasoconstriction in the affected brain areas where vasoparalysis and loss of intercellular fluid occur during venous return. Vasoconstriction stops the slow escape of protein liquid and white blood cells. Administering HBO decreases cellular edema and diminishes the metabolic acidosis seen in stroke.¹⁴ In contrast, for reducing edema of the brain following stroke, osmotic diuretics and other dehydrating agents cause fluid to withdraw from normal brain parts but produce a rebound effect after cessation of therapy. Swelling tends to recur. Also, diuretics do not improve oxygenation.¹⁵

Activation of dormant neurons in the penumbra-Because the penumbra

zone is a brain area between the normal and infarcted tissues, it contains the so-called dormant or idling neurons that must be activated to accomplish recovery.¹⁶ These neurons are nonfunctional but remain anatomically intact and can be revived.

Relief of spasticity-Resistance to passive movement of a stroke patient's limb that gives way as more pressure is applied is known as spasticity. It is the greatest obstacle to proper physical therapy. HBO has proven to be an effective and nontoxic drug and management procedure against poststroke spasticity.¹⁷

Studies Prove Efficacy

Of eight studies carried out on dogs, gerbils, rats, and cats in which cerebral ischemia was induced (equivalent to stroke in humans), seven revealed reduction of the individual animal's symptoms following HBOT treatment.¹⁸⁻²⁵ In the one experimental failure, the researchers admitted that cerebral protection was modified by the anesthesia used during surgery on the dogs. The anesthetic probably increased capillary vasoconstriction, thus nullifying the beneficial effects of HBO.²⁶

More than 1000 patients who sustained cerebrovascular disease have been treated with HBOT and have shown improvement that ranges from 40 percent to 100 percent. This remarkable recovery rate, reported from a number of clinical studies, was much higher than the rate for conventional treatment methods of managing stroke. It is all the more dramatic when one considers that most of the patients participating in these studies were

in the chronic poststroke stage, with fixed neurologic deficits.³

In one such study, for example, 35 patients were treated with HBO on an average of 10 weeks after their CVIs were in the chronic poststroke stage of internal carotid occlusion. HBOT was administered to them at 1.5 ATA for 40 minutes daily and continued for 2 weeks. Fifteen patients improved neurologically, and subsequent extracranial/intracranial (EC/IC) arterial bypass was performed to enhance their improvement. Another 15 patients did not improve from HBOT, and were not operated on. Five more patients who did not improve with HBOT underwent EC/IC bypass but still did not improve. The investigators, therefore, used HBO as a guideline in the selection of patients for EC/IC bypass. As a predictive test, response to HBO is a positive sign of reversibility of the brain lesion and an indicator of continuing improvement after cerebral revascularization.²⁷

In another study, 122 patients in both the acute and the chronic stages of strokes caused by thrombosis were treated with HBO after they failed to respond to conventional medical and physical therapies. At 1.5-2 ATA, HBO was administered with adjusted durations and frequencies according to the patients' current signs of improvement. The duration of sessions was as long as 1 hour and as frequent as every 6-12 hours. Of 79 people receiving HBO treatment after the onset of stroke, 65 percent experienced improvement in quality of life. The HBOT patients spent much less time in the hospital-averaging only 177 days-than did other stroke patients who received conventional treatment and remained hospitalized for up t

The investigator examined his patients inside an HBO chamber during their treatment and documented the improvement of motor power and spasticity.

287 days.²⁸ This is an important consideration in our currently cost-conscious medical arena.

In a final study, HBO produced improvement in every patient, with a total absence of nonresponders. The investigator, K.K. Jain, M.D., a professor and neurosurgeon, who is now an independent consultant in hyperbaric medicine in Engelberg, Switzerland, examined his patients inside an HBO chamber during their treatment and documented the improvement of motor power and spasticity. This improvement was made permanent when combined with physical therapy and when the treatments were repeated daily. 17

References

1. Ancowitz, A. *Strokes and their Prevention*. New York: Van Nostrand Reinhold, 1975, p. 11.
2. Leary, W.E. More early attention to rehabilitation is urged in stroke cases. *The New York Times*, May 28, 1995, p. 19.
3. Jain, K.K. *Cerebral Insufficiency*. Chicago: Year Book Medical Publishers, 1990.
4. Pinkowish, M.D. Strokes: Stop the nihilism (or, time is brain). *Patient Care* August 15:19, 1995.
5. Moretti, J.L. The diagnosis and prognosis of cerebral vascular diseases using early and late SPECT with N-isopropyl-p (1-123) amphetamine (IMP) on 35 patients. *Japapese J Nucl Med* 23:1121-1124, 1986.
6. Astrup, J., Siesjo, B.K., Symon, L. The state of penumbra in the ischemic brain: Viable and lethal threshold in cerebral ischemic. *Stroke* 12:723-725, 1981.
7. Neubauer, R.A., Kagan, R.L., Gottlieb, S.F., James, P.B. [Letter]. *Lancet* March 3, 1990.
8. Mountz, J.M., Modell, J.G., Foster, N.L., et al. Prognostication of recovery following stroke using the comparison of CT and technetium-99 HM-PAO SPECT. *J Nucl Med* 31:6-66, 1990.
9. Neubauer, R.A. The effect of hyperbaric oxygen in prolonged coma: Possible identification of marginal functioning brain zones *Med Subacquea Iperbarica Minerva Med* 5(3):75-79, 1985.
10. Roski, R., Spetzler, R.F., Owens, M., et al. Reversal of seven-year vision field defect with extracranial-intracranial arterial anastomosis. *Surg Neurol* 10:267-268, 1978.
11. Neubauer, R.A., Gottlieb, S.F. Stroke treatment [Letter]. *Lancet* 337:1601, 1991.
12. Boerema, I., Meyne, N.G., Brummelkamp, W.H., et al. Life without blood. *Arch Chirurg Neederlandic* 11:70, 1959.
13. Shalkevich, V.B. Use of hyperbaric oxygen in paroxysmal states due to vertebrobasilar insufficiency. *Vracho Delv* 73, 1982.
14. Kaasik, A.E., Dimitriev, K.K., Tomberg, T.A. Hyperbaric oxygenation in the treatment of patients with ischemic stroke. *Zh Nevropatol Psikhiatr* 88:38-43, 1988.
15. Brown, J.A., Preul, M.C., Taha, A. Hyperbaric oxygen in the treatment of elevated intracranial pressure. *Paediatr Neural* 14:286-290, 1988.
16. Simon, L. The concept of threshold of ischemic in relation to brain structure and function. *J Clin Pathol* 11(Suppl.):149-154, 1976.
17. Jain, K.K. Effect of hyperbaric oxygenation on spasticity in stroke patients. *J Hyperbaric Med* 4:55-61, 1989.
18. Smith, G., Lawson, D.D., Renfrew, S., et al. Preservation of cerebral cortical activity by breathing oxygen at 2 ATA pressure during cerebral ischemic. *Surg Gynecol Obstet* 113:13, 1961.
19. Whalen, R., Hayman, A., Saltzman, H. The protective effect of hyperbaric oxygen in cerebral ischemic. *Arch Neural* 14:15, 1966.
20. Moore, G.F., Fuson, R.L., Margtolis, G., et al. An evaluation of the protective effect of hyperbaric oxygenation on the central nervous system during circulatory arrest. *J Thorac Cardiovasc Surg* 52:618, 1966.
21. Corkill, G., Dhousen, K., Hein, H., et al. Videodensimetric estimation of the protective effect of hyperbaric oxygen in the ischemic gerbil brain. *Surg Neural* 24:406, 1985.
22. Shiokawa, D., Fujishima, M., Yanai, T., et al. Hyperbaric oxygen therapy in experimentally induced acute cerebral ischemic. *Undersea Biomed Res* 13:337, 1986.
23. Burt, J.T., Kapp, J.P., Smith, R.R. Hyperbaric oxygen and cerebral infarction in the gerbil. *Surg Neural* 28:265, 1987.
24. Weinstein, P.R., Hameroff, S.R., Johnson, P., et al. Effect of hyperbaric oxygen therapy or dimethylsulfoxide on cerebral ischemic in unanesthetized gerbils. *Neurosurg* 18:528, 1986.
25. Reiten, J.A., Kien, N.D., Thorup, S., et al. Hyperbaric oxygen increases survival following carotid ligation in gerbils. *Stroke* 21:119-123, 1990.
26. Jacobson, I., Lawson, D.D. The effect of hyperbaric oxygen on experimental cerebral infarction in the dog. *J Neurosurg* 20:849, 1963.
27. Holbach, K.H., Wassmann, H., Hoheluchter, K.L., Jain, K.K. Differentiation between reversible and irreversible post-stroke changes in brain tissue. *Surg Neural* 7:325, 1977.
28. Neubauer, R.A., End, E. Hyperbaric oxygenation as an adjunct therapy in strokes due to thrombosis. *Stroke* 11:297, 1980.

Morton Walker, D.P.M., a former practicing doctor of pediatric medicine, is the author of numerous books and articles, including *Hozo to Stop Baldness and Regrozo Hair* and *The Healing Powers of Chelation Therapy*, coauthored with John Parks Trowbridge, M.D., both published by New Way of Life, Inc., Stamford, Connecticut.

To order reprints of this article, write to or call: Karen Ballen, ALTERNATIVE & COMPLEMENTARY THERAPIES, Mary Ann Liebert, Inc., 2 Madison Avenue, Larchmont, NY 10538, (914) 834-3100.

© Copyright 1995 by Dr. Morton Walker.