

*High Dose Oxygen Therapy for
Cerebral Palsy and the Brain
Injured Child
(Documentation via SPECT
Imaging)*

*R. A. Neubauer, MD, Medical Director, Ocean Hyperbaric
Neurologic Center, USA*

*Observations on blood flow and metabolism in brain damaged children
responding to hyperbaric oxygenation and the world wide clinical
findings of its benefit.*

Purpose

The purpose of this presentation is to document the positive clinical changes that are associated with the use of hyperbaric oxygenation in children with cerebral palsy and brain injuries.

Summary

Cerebral Palsy is a term that encompasses many etiological factors in children diagnosed in utero to age fourteen. Problems may present in utero, peri-natal, and post-natal. Infections, traumatic brain injury, near-drowning, and strokes in children suffering from neurological problems come under the heading of Cerebral Palsy. Hyperbaric oxygenation not only relieves hypoxia but also jumpstarts the brain to much better organization and function. In the very young, it produces a better internal milieu for the growth of new brain tissue. Compelling studies around the world were presented at conferences in Boca Raton, Florida in July of 1999 and 2001.¹ This is well known therapy for the neonates in China,²

Russia,³ and South America.⁴ In certain of these areas, hypoxic or neurologic involved infants are taken from the delivery room to the hyperbaric chamber. The clinical effects are remarkable.

In the following paper we will suggest a specific protocol, present three case reports showing functional brain changes that occur in cerebral palsy patients with the use of hyperbaric oxygenation. Although no double blind controlled studies have been published, functional brain imaging before and after hyperbaric oxygenation, with this close clinical parallel, yields substantial documentation.

Case reports showing dramatic improvement in functional brain imaging paralleling clinical improvement will be presented as part of this paper. These are representative of the 228 patients that have now been treated at the Ocean Hyperbaric Center.

Introduction

In 1964, Hutchinson published, in *The Lancet*,⁵ the use of Hyperbaric oxygenation in severely cyanotic children. They were exposed to extremely high pressure (unsafe now) but their statistical percentage of recovery of the infants was positive. No attention was paid to this observation. In 1989, at the conference of New Horizons for Hyperbaric Oxygenation, Orlando, Florida, Dr. Machado⁴ from San Paolo, presented a large series of cerebral palsy patients that have been treated in the early stages with hyperbaric oxygenation yielding significant results. In China² and Russia,³ administration of hyperbaric oxygenation to cerebral palsy and brain injured children is almost routine. There is currently a hyperbaric trust in the United Kingdom where three hundred cerebral palsy patients are now being treated under the direction of Dr. Phillip James. A branch of this is also in South Africa where two hundred patients are currently under treatment. In a study performed and published at McGill University,⁶ the results were so encouraging that a grant was funded and a double blind study was performed but not published.

To date, over one thousand cases around the world have been treated with hyperbaric oxygenation. There are many centers in Canada, the UK, China, Russia, South America, and South Africa. The results are compelling. The biggest push for continuation of this research are Mothers, who are a driving force and will do anything for their children. Observations show that the earlier the treatment is instituted the more favorable the results. Severe cases in Mexico City are now taken from the delivery room to the chamber room and far less disabilities result and many less treatments are required to rectify the potential damage.

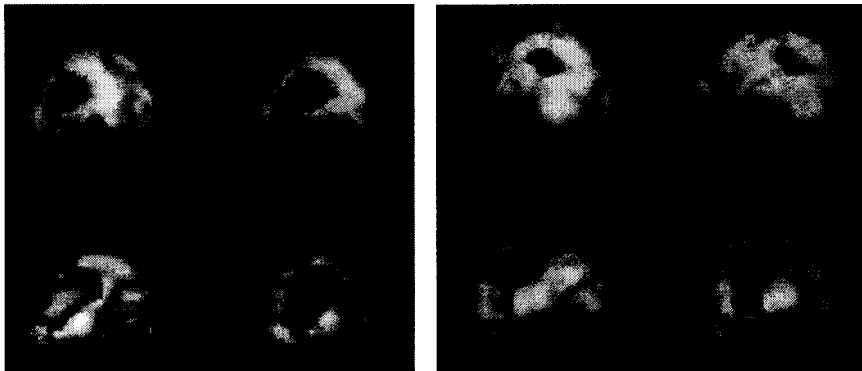
Materials and Methods

To date, 400 cerebral palsy patients and brain injured children have been treated at the Ocean Hyperbaric Center. In most of these patients, SPECT imaging was performed before, during, and after hyperbaric oxygenation exposure. An Elscint single head gamma camera was used for the imaging procedure with a tracer of 99 HMPAO either Ceretec or Neurolite. The dose was calculated according to the child's weight. In no instance was an anesthetic used for restless and crying children. Small amounts of Sodium Butisol and Chloral Hydrate were administered orally, or a child's dose of Valium or Nembutal was administered by suppository. Rarely, injectable Valium or Ativan was used. The patients were all treated in a Vickers monoplace chamber and the pressure ranged between 1.1 ATA and 1.75 ATA. At no instance was it necessary to have a myringotomy performed. Seizure disorder was not a contraindication and frequently treated in this series. The pressure for seizure disorder patients was 1.1 to 1.25 ATA and for non-seizure disorder patients, 1.5 ATA was used with an occasional rise to 1.75 ATA after forty exposures. The treatments were one hour of pressure, two times a day with a four-hour separation in between treatments to avoid any possible oxygen toxicity. The total number varied from patient to patient and ranged from twenty to three hundred treatments. The age was

from six weeks to fourteen years. Besides the scientific documentation with imaging, all cases were followed by an attending physician, therapists, hyperbaric oxygenation technicians, and nursing staff for fine and gross motor control, changes in spasticity, cognition, hearing, vision, nutrition, reduction in secretions (when tracheotomy was present), and a number of cases had a successful removal of the PEG tube. Prior to emersion, a history and physical, and neurological examination were performed by a physician. Their ears were always checked thoroughly and cleared of wax p.r.n.

Case Reports

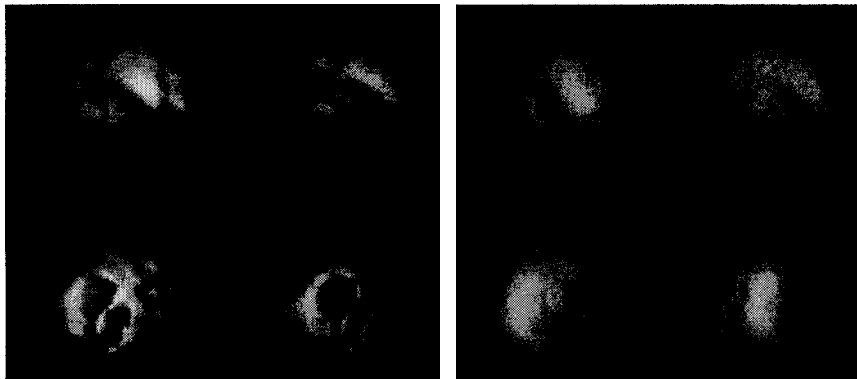
1. D.A.



A five and a half year old white male who weighs 301bs. His birth weight was normal. Pregnancy went to term and the labor was induced with Pitocin. There was fetal distress during delivery. The patient was delivered vaginally with forceps. Upon delivery the patient was not breathing and was bagged. He was then put on a ventilator and sent to the ICU at a major pediatric hospital which was 2.5 hours away. Nearly six days later, he was given seizure medicine and the parents were led to believe that everything was fine. At the age of six months, he was taken to a developmental clinic because of developmental delays. They were informed that he had cerebral palsy with minimal head and trunk control. He was unable to stand without assistance and was unable to hold his

head up. He had no fine motor skills. The patient had to be fed and was able to swallow. He had been receiving physical therapy, occupational therapy, and speech at home and attended a child developmental center five days per week. When seen, the patient gave a history of recurrent seizure disorder and was currently taking Tegretol. The patient was very small for his age. He had spastic diplegia, hyporeflexia, and some generalized dystonia. He had poor cerebellar control. His vision and auditory seemed to be normal. An MRI prior to being seen at the Ocean Hyperbaric Center showed an absence of white matter in both hemispheres. Absence of the splenium of the corpus callosum. The patient was begun on hyperbaric oxygenation of 1.25 ATA with seizure precautions. By the 30th treatment, it was possible to discontinue his Tegretol and no further seizures were noted during the entire course of the therapy. The pressure was then raised to 1.5 ATA and the patient improved substantially. He was able to sit up, hold his head up, turn over, begin to crawl, could walk with help, the spastic diplegia was virtually gone, the balance was better, and the patient was eating better and seemed to be gaining weight and growing rapidly. The family was very pleased. The SPECT scan showed considerable improvement particularly in relationship to the entire right hemisphere and also substantial improvement in the area of the left temporal parietal zone. The patient will return at a later date for follow-up treatments.

2. M.M.



A four year old white female with a diagnosis of cerebral palsy at six months of age because of developmental delays. It was found that the mother had cytomegalovirus. The patient's weight is only 22 lbs. and has marked dystonia. The patient cannot crawl; spasticity is more marked in the upper limbs, there is modest spasticity with some spastic diplegia of the lower limbs but the patient rarely moves her lower legs. The patient has required hearing aids because of auditory impairment. There are visual defects. She is able to eat soft food and drinks fluids well; no swallowing problems. There is normal tactile/visual stimulation. There is quad spasticity, microcephaly. The heart and lungs are normal. The initial SPECT scan of 3/23/99 showed thinning of the left frontal lobe. There are patchy areas of hypoperfusion especially in the right temporal occipital zone. The patient had 149 hyperbaric oxygenation exposures and showed significant improvement particularly in the frontal lobes and clearing of the deficits in the right occipital zone. The patient is much more alert. The spasticity was reduced, she is still unable to crawl but is moving more and turning over from side to side, but not from her stomach. She is more vocal and is attempting to speak. The patient will return in three months for further treatment and a possible use of growth hormone.

Discussion

Clinical observation shows that the sooner hyperbaric oxygenation is administered, the more optimum the outcome. With newer imaging techniques such as ultrasound, SPECT scanning, and functional MRI and TCD (transcranial Doppler), a diagnosis can be made very early and therapy could begin immediately rather than wait for developmental delays. In seizure disorder, the amount of anti-convulsive medication was frequently reduced with the permission of the attending pediatric neurologist. At the end of the session, patients were given copies of their SPECT scans with full reports to take home to their attending physician or neurologist. The initial course should be close to forty treatments. It is not necessary to have a lag or a break after forty treatments as certain centers are recommending. At Ocean Hyperbaric Center the treatment is continued as long as logistics provide for it and the clinical improvement may be substantiated along with improving functional imaging studies. Ideally, the patient should continue treatment on a continuing basis as long as possible since this is a cumulative effect. A certain number of our patients have taken up to three hundred exposures and other patients, however, one thousand would do no good. A close parallel between functional imaging and clinical observations exists. A certain number of patients with limited eyesight or blindness had marked areas of hypoperfusion at the occipital cortex bilaterally. Upon restoration of the flow and metabolism of this area, varied degrees of vision returned. The most common finding has been the overall reduction in spasticity, especially the scissoring gait and dyplasia. Dystonia has improved significantly. In a large percentage of the patients, the PEG tube has been removed following consultation with the speech therapist and a barium swallow. In nearly all of the cases, tracheostomy has also been discontinued or the secretions have been reduced dramatically. Cognitive, fine and gross motor control, trunk control, and ambulation have all improved. In nearly all cases, the mothers were quite pleased.

Conclusion

The effects of hyperbaric oxygenation on the brain are that it reduces cerebral edema, deactivates platelets, reduces lactate peaks and toxic amines, restores the integrity to the blood brain barrier and cell membrane, enhances the delivery of oxygen to DNA and mitochondria, neutralizes free radicals, and delivers oxygen to the cells for immediate metabolic use without energy exchange even in the absence of circulation. Theoretically the use of hyperbaric oxygenation in cerebral palsy irrespective of its causes will not only correct the hypoxic state in little ones but will give the brain a better environment in which to grow new tissue. Seizure disorder may be actively treated with hyperbaric oxygenation which is standard in China.? We have treated sixty cases with current seizure disorder and have been able to reduce the frequency of seizures in nearly every case as well as being able to reduce most of the medications. Thus seizure disorder is not a contraindication for hyperbaric oxygenation in cerebral palsy and the brain injured child when the dose is appropriate. As noted previously, the dose here is 1.1 to 1.25 ATA, 1 hour at pressure, two times a day with at least a four-hour separation. The exact dose of hyperbaric oxygenation is not known. The earlier the administration the less disability . The pressures range from 1.1 to 1.75 ATA, one hour each session, one to two times per day. Certain patients may require up to 400 treatments with continuing improvement - yet with other patients, 1000 treatments would do no good. It will be at least ten years before we know the results of these early observations. Hopefully, eventually controlled longitudinal studies will be achieved so that this will become a mainstream part of medicine and reimbursed by insurance companies

REFERNCES

1. 1st International Symposium on Cerebral Palsy and the Brain Injured Child, Boca Raton, FL, July, 1999. Proceedings of the 2nd International symposium on Hyperbaric Oxygen and the Brain Injured Child. Jim Joyner, Ed. Best Publishing, Flagstaff, AZ, 2002.
2. Qibiao W, Treatment of Children's Epilepsy by Hyperbaric oxygenation: Analysis of 100 cases. Proceedings of: 11th International Congress on Hyperbaric Medicine, Fuzhou, China; Best Publishing: p 79-81
3. Baiborodov B., The effects of Hyperbaric oxygenation Free Radical Oxidation and Antioxidant System of Blood in the Newborn who had Acute Hypoxia at Birth, *Anesteziol Reanimatol* 1996 Nov Dec; 56-58.
4. Machado J., Clinically observed reduction of spasticity in patients with neurological diseases and in children with cerebral palsy from hyperbaric oxygen therapy, Proceedings of New Horizons in Hyperbaric Medicine - American College of Hyperbaric Medicine, 1989.
5. Hutchison J., Kerr M., Williams K., Hopkinson W., Hyperbaric Oxygen in Resuscitation of the Newborn, *The Lancet*, 1963, Vol. 2, 1020-1022
6. Montgomery D., Effects of Hyperbaric Oxygen Therapy on Children with Spastic Diplegic Cerebral Palsy: A Pilot Project, *Journal of Undersea & Hyperbaric Medicine*, Vol. 26: No. 4: Winter 1999: p 235 - 242.
7. Sanchez, EC, Montes G, Elizondo C, et al. Emergency lifesaving us of high dose oxygen in neonates. In press, 2002