

Hyperbaric Oxygen as an Adjunctive Therapy for Threatened Post Mastectomy Skin Flaps in the Setting of Staged Prosthetic Breast Reconstruction

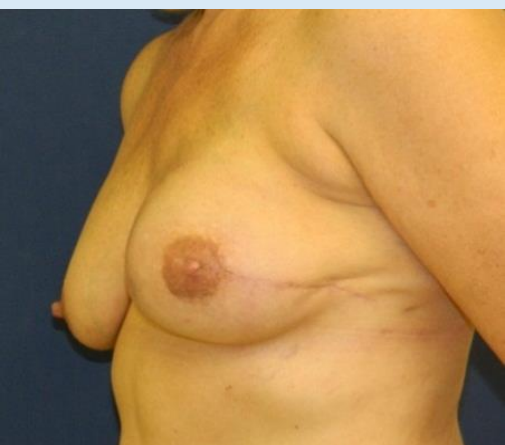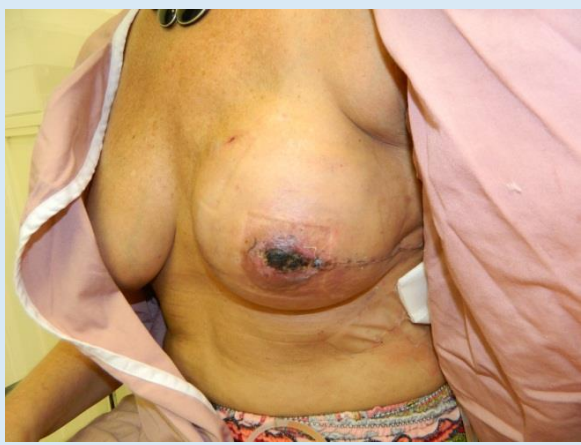Donovan Rosas, MD, Laura Sudarsky, MD, FACS, Michele Gilbert MSN, NP-C, Good Samaritan Hospital. Suffern, N.Y. Glenn J. Butler, CHT- Life Support Technologies group. Tarrytown, N.Y.
Good Samaritan Regional Medical Center Wound and Hyperbaric Institute Suffern, NY

ABSTRACT

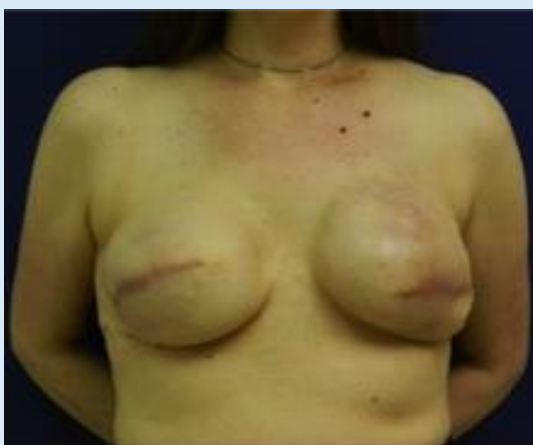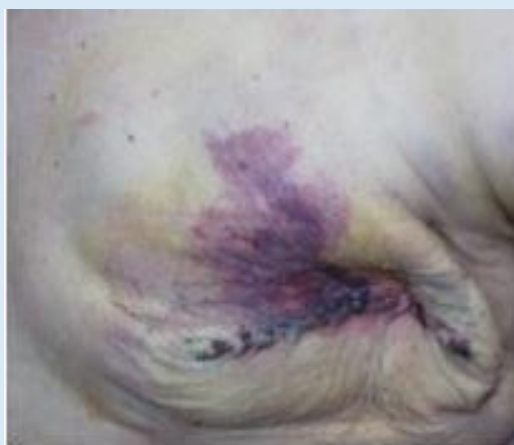Mastectomy skin flap necrosis and subsequent incisional dehiscence in the setting of implant-based reconstruction is a serious complication. We have identified a cohort of patients with threatened skin flaps and intervened with early hyperbaric oxygen therapy (HBOT) with the goal of avoiding eventual dehiscence and exposure of the tissue expander. When candidates are identified and treatment initiated in a timely fashion, salvage is possible. We will demonstrate the effectiveness of this adjunctive intervention in conjunction with early surgical revision in the setting of staged implant based reconstruction. Patients with threatened post mastectomy skin flaps were treated with HBOT (2.5 atm 90 minutes, 4-5 sessions per week) in the immediate peri-operative period. Flap viability was assessed weekly. Once the threatened ischemic area stabilized, patients were returned to the operating room for partial flap debridement, pulse lavage, and primary closure as needed. These patients are compared to a control group treated conservatively with local wound care alone. Five patients were treated at Good Samaritan Regional Medical Center with Hyperbaric Oxygen (according to protocol). 5/6 had successful completion of their reconstructions. The lone treatment failure occurred in an irradiated patient who subsequently underwent explantation. One patient did not require surgical debridement of her mastectomy flap and went on to successful completion of her reconstruction. Compromised mastectomy skin flaps typically result in exposure and loss of tissue expanders in staged breast reconstruction. Hyperbaric oxygen, when employed early may improve the potential for reconstructive salvage.

PURPOSE

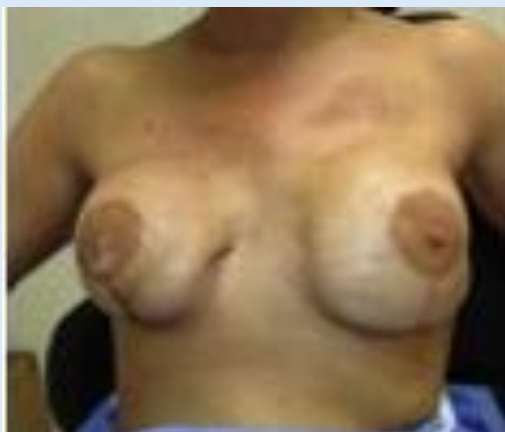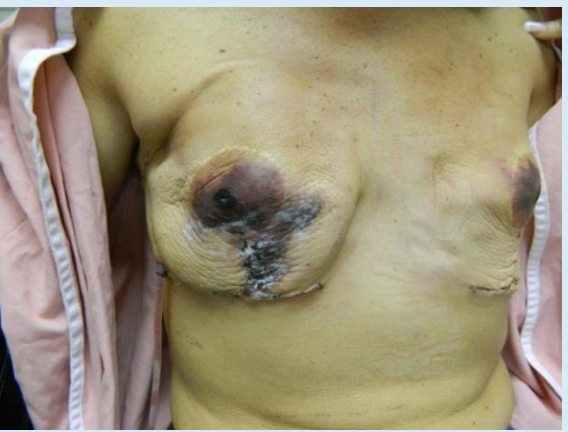We will demonstrate the effectiveness of hyperbaric oxygen as an adjunctive intervention in conjunction with early surgical revision in the setting of staged implant based reconstruction with threatened mastectomy skin flaps.



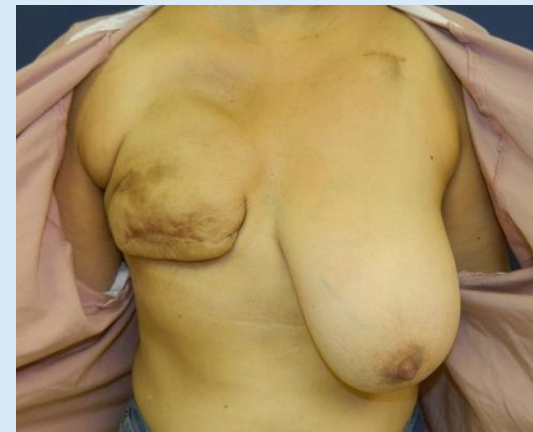
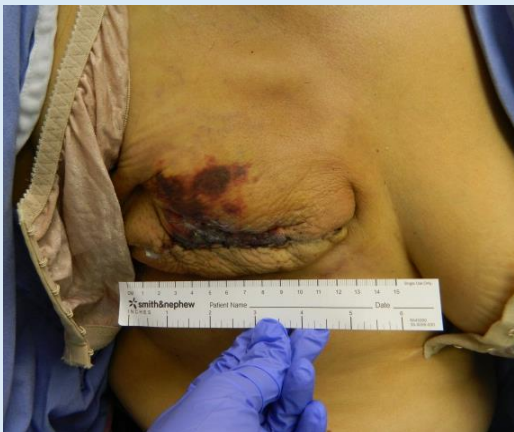52 yo s/p staged reconstruction, HBOT initiated at 8 days, 20 treatments > reconstructive salvage



48 yo s/p staged breast reconstruction, HBOT initiated at 7 days, 13 treatments > reconstructive salvage



44 yo smoker with prior breast reduction s/p staged breast reconstruction, HBOT initiated at 2 days, 23 treatments > reconstructive salvage



50 yo smoker s/p staged breast reconstruction, HBOT initiated at 3 days, 13 treatments > reconstructive salvage

RESULTS

- In total over a 4 year period **we treated** 15 patients with post mastectomy threatened skin flaps. 8 of these were treated with HBOT and 7 were treated with conservative measures only.
- Among the treated patients, the average time to treat was 12.75 days, with an average of 18 treatments. Salvage rate was 87.5%
- 85.7% patients treated conservatively suffered a reconstructive failure.
- The lone failure following HBOT was observed after a significant delay in initiation of therapy (42 days)



The Hyperbaric Unit at Good Samaritan Regional Medical Center

CONCLUSIONS

- Upon review of our experience of the salvage of reconstructed breast in the setting of threatened mastectomy skin flaps, the following conclusions can be made:
- Mastectomy skin flap necrosis is one of the most significant threats to successful breast reconstruction. Early identification of these compromised flaps or at risk patients (nipple sparing mastectomies, tobacco use, XRT) is crucial to salvage.
 - Our success rate for reconstruction in the setting of threatened mastectomy skin flaps when HBOT is employed is 87.5%. This compares to a 14.2% success rate in cases where HBOT is not employed.
 - Early initiation of HBOT is crucial to success with a average time to treatment of 8.57 days. The lone failure demonstrated at significant delay with regards to treatment initiation.
 - Early HBOT and aggressive surgical debridement when employed in an early effective manner can salvage reconstructions and improve patient outcomes.

Demographic	Cohort Average
Age	49.375
BMI	24.96
Tobacco	50%
Breast Cup Size	C-cup (37.5%)
Pathologic Diagnosis	DCIS (62.5%)
Operation	Stage I Reconstruction (91.6%)
Breast Resection (gm)	666.18 gm
Complication	Threatened Flap (62.5%)

